

EVALUATION OF COLON ANASTOMOSIS HEALING PERFORMED BY “MANUAL TECHNIQUE”

V. V. Leonov, A. V. Abbas Hamed, Leonov,
Sumy State University Medical Institute, Sumy, Ukraine

The main disadvantages of forming large intestine anastomosis "manually" are technical defects. The formation of telescopic anastomosis by invagination is dangerous with ischemic disorders. 373 patients were operated with colon and rectal anastomosis formation; 227 of them - with "end to end" anastomosis, 129 patients with "side to side" anastomosis and 17 patients with "end to side" anastomosis. Among the 227 patients with "end to end" anastomosis 48 patients appeared to be formed with telescopic colorectal anastomosis. Anastomoses performed with "hand technique" after 70 days of formation were fully functional with complete reparative processes in the serous level.

Key words: "manual technique" of colon anastomosis, intestinal anastomosis.

INTRODUCTION

In the process of formation and development of abdominal surgery, research for the best way to restore intestinal tube after resection is constantly going on, and discussions about the right type of intestinal suture and preventive measures of anastomosis failure are still relevant [1, 2].

The problem of applying intestinal sutures and anastomoses and the appearance of inconsistency is one of the central problems in surgery. This poses high difficulty and supports the fact that despite a large number of fundamental researches to develop new methods and ways of applying intestinal sutures and anastomoses, practical results are far beyond the expectations of surgery [3-6].

Thus, there is a number of questions to be answered on the causes of most studies conducted without results. It is possible that several provisions of the problem are inconsistent and need to be rethought and revised, as prevailing traditional views on these or other laws may even have false dogmas.

Contradictory is assessing the causes of failure of intestinal anastomoses and sutures, resulting in a controversial tactic of most studies, heterogeneity of the groups being compared, as well as researcher's arbitrary trips to the treatment of the underlying causes of complications [7, 8]. Complications are associated with the absence of an open-minded approach. Therefore, the primary condition of our study was to quantify the factors directly or indirectly affecting the healing of the anastomosis. This problem was solved by the formation of study groups: the group of healing anastomosis and anastomosis of insolvency. Comparing the frequency of factors in the groups, we were able to identify and prioritize each factor. Prioritization of factors was the basis for predicting failure in patients with impending surgical intervention. Also, it was possible to determine the degree of complications that influenced the administration of treatment strategy and proactively eliminated unfavorable factors.

In our work we set a goal – to study the state of large bowel anastomosis healing performed by "manual technique".

Functional and morphological assessment of visual healing of anastomosis was performed according to the following parameters:

A. Clinical evaluation of postoperative period for the severity and duration of intestinal paresis.

B. The study of the nature of the passage of intestinal content in the submersible anastomosis.

C. Visual assessment of anastomotic healing of fistulas, as well as colorectal anastomosis on the probe.

D. The nature and causes of complications submerged healing of anastomoses.

MATERIALS AND METHODS

373 patients were observed and operated on the colon and rectum with a “manual technique” anastomosis. 362 observations showed: 97.1 % of operations were carried out in a planned manner; 90.9 % (339 patients) had oncological pathology of the colon and rectum; 54 % (202 operated patients) appeared to be male patients.

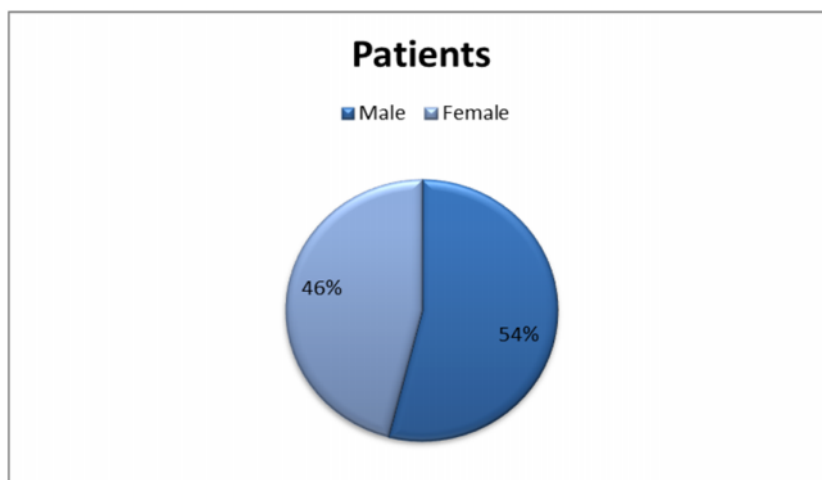


Fig. 1 - Distribution of patients by gender

The average age of patients was 62.5, while patients aged 60 and older numbered 59.2 % (221 patients).

Table 1 – Name and number of observations for each type of the disease

The name of the disease	Number of observations	Percentage, %
Polyposis of the colon	7	1.9
Inflammation of the colon	3	0.8
Cancer of the right part of the colon	107	28.7
Transverse colon cancer of the colon	15	4.0
Cancer of the descending colon	45	12.1
Cancer of the sigmoid colon	112	30.0
Rectosigmoid carcinoma of the ampullar and upper section of the rectum	84	22.5
In total	373	100

Table 2 – Number and type of operations

Operations	Number of patients	Percentage, %
Anastomosis bypass	18	4.8
Right-sided hemicolectomy	106	28.4
Resection of the transverse colon	17	4.6
Left-sided hemicolectomy	42	11.3
Resection of the sigmoid	101	27.1
Anterior resection of the sigmoid colon	89	23.8
In total	373	100

The motor-evacuation function of the gastrointestinal tract was studied in 48 patients, with telescopic invaginated anastomosis - 31 patients, (Fig. 2) and with invaginated colorectal anastomosis - 17 patients (Fig. 3), at the same time taking into account the occurrence of intestinal peristaltic noises and starting date of flatus passing and stool recovery.

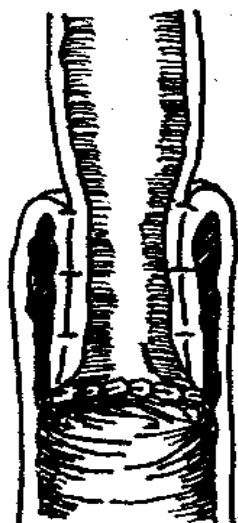


Fig. 2 – “Hand technique” telescopic invaginated colon anastomosis

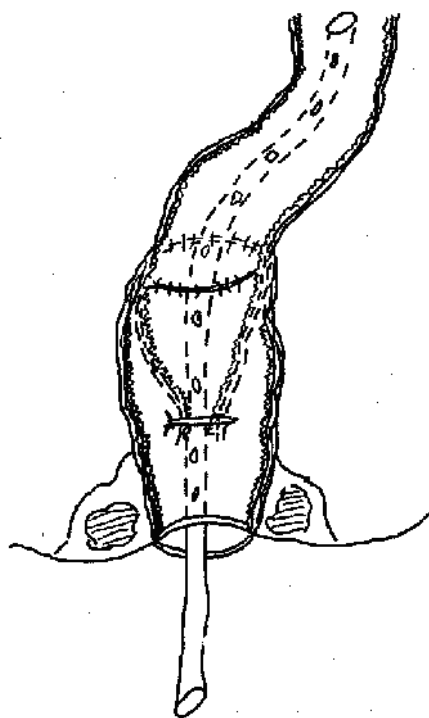


Fig. 3 – “Hand technique” colorectal anastomosis by invagination

“End to end” anastomosis was performed in 227 patients (60.9 %), “side to side” anastomosis was performed in 129 patients (34.5%) and “end to side” – in 27 patients (4.6%). Out of 227 cases, “end to end” anastomosis was performed in 48 patients (21%) and colonic anastomosis was not submerged.

RESULTS AND DISCUSSIONS

The first signs of intestinal peristalsis were identified on the first postoperative day in 4 patients (8.3 %), on the second day – in 32 patients (66.7 %) and on the third day the rest 12 patients (25.0 %).

It was found that the recovery time of peristalsis depended on the severity of surgical intervention: all cases with lymph node dissection laparotomy, as well as cases of resection of the transverse colon in its middle third, followed by a more pronounced and prolonged postoperative period. That seemed to have contributed to the injury of the root of the mesentery and retroperitoneal space.

Interpretation deserved a separate state of motility in 17 colorectal anastomosis observations: the cases of bloating or cramping enhanced in this group of patients were not observed. This was aided by decompression of the colon which ensured a constant discharge of the contents.

An independent stool recovered patients with telescopic handling invaginated anastomosis to the 4th (35.5 %) and 5th (64.5%) days.

The formation of invaginated anastomosis may be complicated by intestine lumen stenosis.

For this purpose, we used two methods of X-rays: the ordinary oral administration of liquid barium suspension (50 ml) in 14 patients and the method of X - ray contrast markers: per oral intake of 3 – 5 contrast marks 5-7 mm in diameter with followed dynamic X-ray control – in 9 patients (Fig. 4).

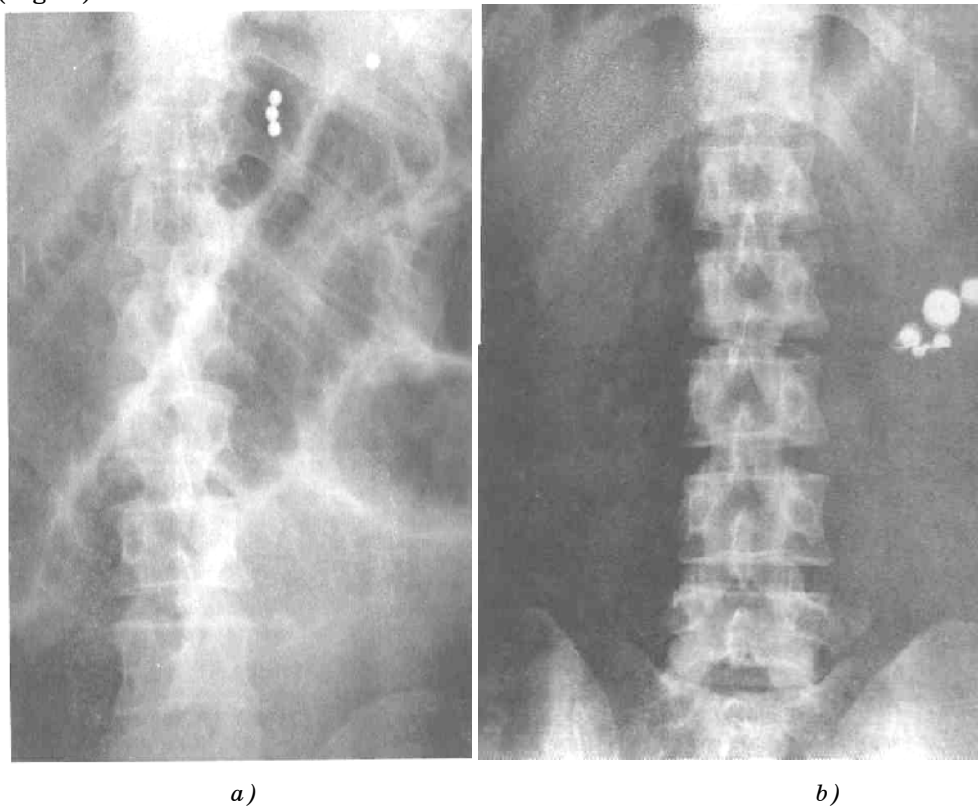


Fig. 4 – X-ray contrast marks method

In these cases, latency barium suspension in the colon was not established. Passage of contrast markers was also free: made with the time interval the granules moved to the intestinal loops separately from each

other and only after 8-15 hours they turned out to be grouped in the left half of the colon (Fig. 5).

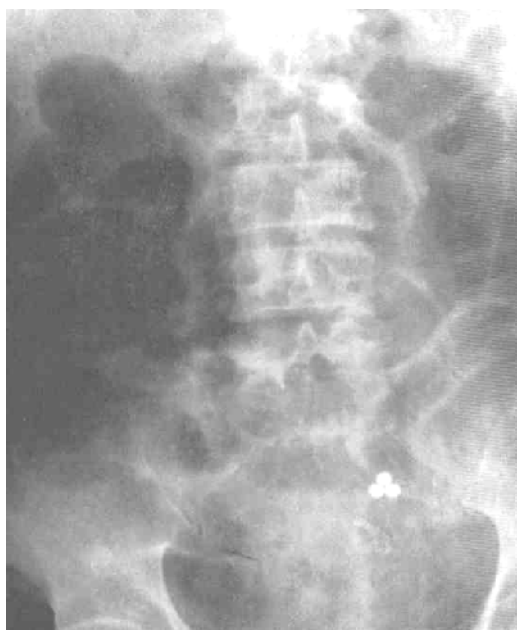

Fig. 5 – Passage of contrast marks after 8-15 hours

In 17 patients a visual evaluation of colon anastomosis healing was performed. From the second day after surgery, when swelling was detected, rectomanoscopy relegated Sigma Plot, swelling increased on the second-third day, and extended to 1.5-2 cm proximally to the ligation. At the same time in all cases on the second day following the edge of bowel, ligatures seemed necrotic, displaying a dark-gray color and spread around the entire circumference. Only a 3-4 day site of necrosis began to spread above the ligature, but no more than 3 mm. And from this area began to appear intestinal contents. Destruction of the intestine (Sigma) through ligation manifested no later than in 4-5 days, but the rejection of tissue necrosis began 6-7 days later. That was accompanied by the release of the probe and its spontaneous loss. However, out of 17 observations, five cases had trans anal hooking necrotic tissue to extract the probe.

During the next 6-7 days, "stump of invaginate" descended into the intestine, remained in a state of edema, the opening of the anastomosis, not exceeding 10 mm in diameter. Some of the swelling extended to the transient groove formed by the serous membrane of the rectum. Defects in this groove were not revealed. By the 15th day of swelling, the stump of the sigmoid colon dramatically decreased the edge around the circumference of intestine freed of necrotic tissue. The hole was left open, the anastomosis increasing in size to 15 mm.

After 27-30 days, when the formation of anastomotic tissue swelling had almost disappeared, it retained only some stiffness in the stump (brush) of the sigmoid colon and the slit-like opening had taken shape.

Only after 70 days formed anastomosis lost its swelling and stiffness and increased anastomotic orifice diameter of 2.5 ± 0.5 cm, and was immediately expanded upon stimulation up to 3.5 ± 0.5 cm. Also observed was morphological restructuring of the sigmoid colon serosa, introduced into the lumen directly while taking a visual form of the mucous membrane.

We observed 4 cases of complications. Two of them were caused by the opposite direction migration of the telescopic invaginated anastomosis. The other two cases – failure of invaginated colorectal anastomosis which required relaparotomy.

CONCLUSION

“Hand technique” anastomoses by invagination were preferred because their formation in the manual gave a more personal approach. It ensured us that it reduced the risks of insolvency. This tactic in relation to the formation of colonic anastomoses according to the observations showed good results. Material biopsy from the area of anastomosis confirmed good adaptation of the tissues.

ОЦІНКА ЗАЖИВЛЕННЯ ТОВСТОКИШКОВИХ АНАСТОМОЗІВ ВИКОНАНИХ «РУЧНИМ СПОСОБОМ»

В. В. Леонов, Аббас Хамед, А. В. Леонов,

Медичний інститут Сумського державного університету, м. Суми

Основними недоліками формування товстокишкового анастомозу «ручним способом» шляхом інвагінації є технічні дефекти втручання, а при формуванні телескопічного анастомозу шляхом інвагінації можливі ішемічні порушення. 373 пацієнти були прооперовані на товстій та прямій кишках з формуванням анастомозу. Найчастіше формувался анастомоз «кінець в кінець» - у 227 пацієнтів, «бік в бік» - у 129 пацієнтів і «кінець в бік» - у 17 пацієнтів. Із 227 хворих з анастомозом «кінець в кінець» у 48 пацієнтів був сформований телескопічний товстокишковий анастомоз. Анастомози сформовані «ручною технікою» після 70 днів з моменту формування були повністю функціональні, репаративні процеси в серозній оболонці були завершені.

Ключові слова: *формування товстокишкового анастомозу «ручним способом», кишковий анастомоз.*

ОЦЕНКА ЗАЖИВЛЕНИЯ ТОЛСТОКИШЕЧНЫХ АНАСТОМОЗОВ ВЫПОЛНЕННЫХ «РУЧНЫМ СПОСОБОМ»

В. В. Леонов, Аббас Хамед, А. В. Леонов,

Медицинский институт Сумского государственного университета, г. Сумы

Основными недостатками формирования толстокишечного анастомоза «ручным способом» путем инвагинации являются технические дефекты вмешательства, а при формировании телескопического анастомоза путем инвагинации возможны ишемические нарушения. 373 пациента были прооперированы на толстой и прямой кишках с формированием анастомоза. Наиболее часто формировался анастомоз «конец в конец» - у 227 пациентов, «бок в бок» - у 129 пациентов и «конец в бок» - у 17 пациентов. Из 227 больных с анастомозом «конец в конец» у 48 пациентов был сформирован телескопический толстокишечный анастомоз. Анастомозы выполненные «ручным способом» после 70 дней с момента формирования были полностью функциональны, репаративные процессы в серозной оболочке были завершены.

Ключевые слова: *формирование толстокишечного анастомоза «ручным способом», кишечный анастомоз.*

REFERENCES

1. Outcomes of primary repair and primary anastomosis in war-related colon injuries/ A. Vertrees, W. Wakefield, C. Pickett, L. Greer, A. Wilson, S. Gillern, J. Nelson, J. Aydelotte, A. Stojadinovic, C. Shriver // J. Trauma. – 2009. – Vol. 66(5). – P. 1286-1305; discussion 1291-3.
2. Bucher P. Mechanical bowel preparation for elective colorectal surgery - a meta-analysis / P. Bucher, B. Mermillod, P. Gervaz, P. Morel// Arch. Surg. – 2004. – Vol. 139. – P. 1359-1364.
3. Primary resection with anastomosis vs. Hartmann's procedure in nonelective surgery for acute colonic diverticulitis: a systematic review / V. A. Constantinides, P. P. Tekkis, T. Athanasiou, O. Aziz, S. Purkayastha, F. H. Remzi, et al. // Diseases of the Colon & Rectum, 2006. – Vol. 49 (7). – P. 966-981.
4. De Salvo G.L. Curative surgery for obstruction from primary left colorectal carcinoma: Primary or staged resection? / G. L. De Salvo, C. Gava, S. Pucciarelli, M. Lise //

- The Cochrane Database of Systematic Reviews. – 2004. – Issue 2. Art. No.: CD002101.pub2.
DOI: 10.1002/14651858.CD002101.pub2.
5. De U., Ghosh S. Single stage primary anastomosis without colonic lavage for left-sided colonic obstruction due to acute sigmoid volvulus: A prospective study of one hundred and ninety-seven cases / De U., Ghosh S. // ANZ J Surg. – 2003. – Vol. 73. – P. 390-92.
 6. Handsewn versus stapled anastomosis in penetrating colon injuries requiring resection: A multicenter study / D. Demetriades, J. A. Murray, L. S. Chan, C. Ordonez, D. Bowley, K.K. Nagy, et al. // J. Trauma. – 2002. – Vol. 52. – P. 117-121.
 7. Management of colorectal injuries during operation iraqi freedom: patterns of stoma usage / J. E. Duncan, C. H. Corwin, W. B. Sweeney, J. R. Dunne, J. W. Denobile, P. W. Perdue, et al. // Journal of Trauma-Injury Infection & Critical Care. – 2008. – Vol. 64 (4). – P. 1043-1050.
 8. Edino S. T. Intraoperative colonic lavage in emergency surgical treatment of left-sided large bowel lesions / S. T. Edino, A. Z. Mohammed, M. Anumah // Trop. Doc. – 2005. – Vol. 35 (1). – P. 37-45.

Надійшла до редакції 11 липня 2012 р.